

Class II subdivision treatment with tip-back moments

Bhavna Shroff*, Steven J. Lindauer** and Charles J. Burstone***

Departments of Orthodontics, *University of Maryland School of Dentistry, **Medical College of Virginia, Virginia Commonwealth University and ***University of Connecticut, USA

SUMMARY Unilateral tip-back mechanics are challenging because of a number of undesirable side-effects associated with their use during orthodontic treatment. The purpose of this paper is to review the differential diagnosis and treatment planning of Class II subdivision malocclusions and present a treatment strategy based on a careful biomechanical analysis of the clinical situation. Emphasis is placed on the correction of molar axial inclination using unilateral tip-back moments in the treatment of dental asymmetries. Appliance design and treatment sequencing are also discussed.

Introduction

Dental malocclusions involving an asymmetric posterior occlusion which results from the presence of an altered mesio–distal molar axial inclination are difficult to treat orthodontically. One of the challenges in treating such malocclusions is associated with the biomechanical limitations of a technique that uses a continuous archwire approach. Such techniques may limit the full correction of an asymmetric occlusion because of friction between the bracket and the archwire and unpredictable force systems. Furthermore, the correction of asymmetric malocclusions using unilateral tip-back moments is usually accompanied by undesirable side-effects when force systems used during treatment are not carefully analysed and evaluated prior to appliance design. The differential and early diagnoses of dental asymmetries are the keys to defining the correct treatment objectives and designing an appliance which will deliver the desired force system to achieve orthodontic correction.

Diagnosis and treatment planning

Asymmetric malocclusions may result from the presence of a true skeletal asymmetry, a dental asymmetry or a combination of these two clinical situations. During the differential diagnosis of a dental asymmetry, careful evaluation of the antero–posterior relationship

of the buccal occlusion is undertaken in centric relation, and the presence of a functional shift between centric relation and centric occlusion positions is recorded. When the centric relation position is difficult to find, a deprogramming splint may be prescribed to the patient to help establish accurately the centric relation position. It is an important step for ruling out a pseudo-asymmetric buccal occlusion resulting from a shift of the mandible during closure.

Dental asymmetries of the posterior occlusion may result from the presence of a molar malocclusion in the first order (rotation) or the second order (abnormal mesio–distal axial inclination). Although this paper primarily focuses on the diagnosis and correction of dental asymmetries resulting from the presence of an abnormal molar axial inclination, the role of unilateral molar rotation in creating dental asymmetries will also be discussed.

The presence of a unilateral molar rotation in the maxillary arch observed from the occlusal aspect may be an indication of mesial drift and a more Class II molar relationship on that side. During treatment, pure rotation of the molar around the centre of resistance can open space for the anterior teeth (Fig. 1). Early diagnosis and correction of the asymmetry are critical to obtain a bilateral Class I occlusion and an ideal overjet/overbite relationship.

A discrepancy between the mesio–distal axial inclination (second order) of the right and left

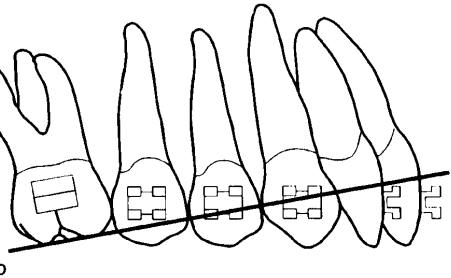
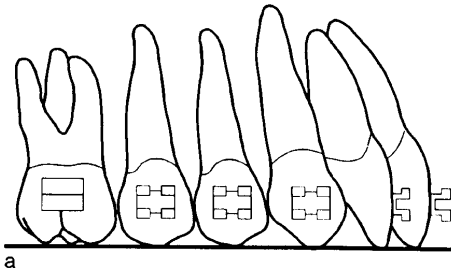


Figure 1 Schematic representation of a rotated maxillary right permanent first molar. The right permanent first molar displays a mesio-lingual rotation and the buccal occlusion on this side is more Class II. Rotation of the first molar using a couple moves the mesial aspect of the molar distally because the molar rotates around the centre of resistance (CR) which is located lingually.

permanent first molars introduces a degree of asymmetry between the right and left buccal occlusion and needs to be diagnosed and corrected during the initial stages of treatment. For example, mesial inclination of the maxillary first molar can be observed in cases of 'ectopic eruption' of the permanent maxillary first molars. This mesial positioning of the maxillary first molar results in a more Class II buccal occlusion on that side of the dental arch. It is therefore necessary to correct the axial inclination of the first molar to achieve an ideal buccal occlusion bilaterally. Dental midline discrepancy and deep overbite are often associated with an asymmetric buccal occlusion and must be carefully evaluated to see if it is possible to address this problem simultaneously during the treatment of the asymmetry.

The mesio-distal axial inclination of the maxillary first permanent molars can be evaluated from study models and lateral

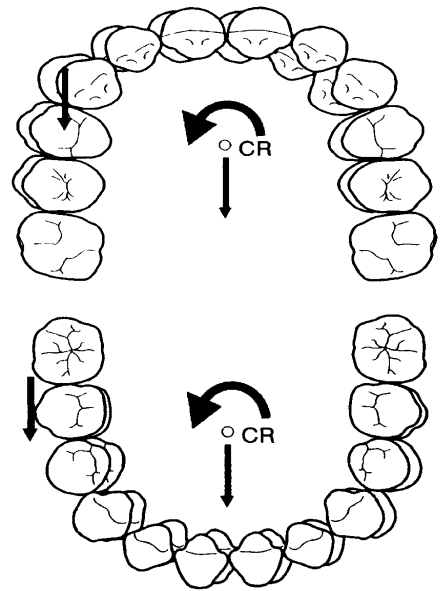


Figure 2 (a) The assessment of the mesio-distal axial inclination of the maxillary first permanent molar is undertaken with respect to an antero-posterior horizontal line passing through the tip of the buccal cusps of the molar. (b) When the maxillary first permanent molar is tipped forward, the horizontal line of reference intersects the maxillary incisor more gingivally than observed in (a).

cephalometric radiographs taken at a 45 degree angulation. The mesio-distal molar axial inclination is evaluated with respect to an antero-posterior horizontal line passing through the tip of the buccal cusps of the maxillary first permanent molars on each side. Clinically, a ruler or a straight edge can be easily aligned to the buccal cusps of the molars and used to establish the horizontal line of reference. The right and left horizontal lines intersect the maxillary incisors and the right and left molar axial inclinations are then compared (Fig. 2a,b).

Radiographic evaluation assists in determining the mesio-distal molar axial inclinations and the space available distal to the first and second maxillary molars. Lateral cephalometric radiographs taken at a 45 degree angulation are useful to assess the mesio-distal axial inclinations of maxillary and mandibular posterior teeth, their root parallelism, the level of the bone and its distribution. Panoramic

and periapical radiographs of the maxillary tuberosity may also be helpful to assess the amount of space distal to the molars. An asymmetry between the mesio–distal axial inclination of the right and left first molars is not self-correcting with growth. The mesio–distal axial inclinations of permanent molars change with favourable growth, but a pre-existing discrepancy between the mesio–distal axial inclinations of the right and left first molars is maintained and results in an asymmetric buccal occlusion. Diagnostic tools such as frontal cephalometric radiographs can also assist in establishing the origin of the asymmetry. A frontal cephalometric film of a patient with an asymmetric occlusion of dental origin may not show any skeletal or apical base discrepancies. Treatment options for severe skeletal asymmetries including frontal horizontal discrepancies between the maxillary and mandibular apical bases range from surgical treatment to orthodontic treatment involving an asymmetric pattern of dental extractions to compensate for the skeletal problem.

Treatment planning of a malocclusion with some degree of asymmetry is a challenging process. In non-extraction therapy, if the difference between the right and left mesio–distal axial inclination of the molars is not diagnosed and addressed early during treatment, the asymmetry between the right and left posterior occlusion is maintained until later in treatment and may then be more difficult to correct. Therefore, the mechanics plan must be designed to address initially the asymmetry of the posterior occlusion so a symmetric occlusion can be achieved early during treatment.

Unilateral tip-back is difficult to achieve using continuous archwire techniques. These techniques do not allow the application of ideal differential force systems on the right and left sides of the arch without significant undesirable side-effects, such as a change in the cant of the occlusal plane, molar extrusion, mesial root displacement of the molar and lower arch effects if Class II elastics are used. A more efficient approach will involve an optimum dissociation between the mechanics used to treat the right and left sides of the dental arch using the seg-

mented arch technique to better correct the asymmetry and control the undesirable side-effects (Burstone *et al.*, 1961; Burstone, 1962, 1966; 1981, 1985; Romeo and Burstone, 1977; Smith and Burstone, 1984). Following correction of the posterior asymmetry and attainment of symmetric right and left buccal occlusions, appropriate mechanics can be used to continue treatment depending on the resolution of any anterior problem.

Biomechanics

Common mechanisms used to achieve unilateral molar tip-back and their side-effects

Various treatment strategies are available to correct dental asymmetries orthodontically, each possessing numerous advantages and drawbacks. This paper is limited to discussing the mechanics of unilateral tip-back. The use of asymmetric headgear (unilateral face bow) has been advocated (Haack and Weinstein, 1958) and provides a mechanism to deliver an asymmetric force system to the maxillary molars (Garland Hershey *et al.*, 1981). Although a distal force can be delivered unilaterally, a net lateral force is also present at the inner bow terminals and has a tendency to create a lingual crossbite on the side which receives the greater distal force. However, good patient co-operation is necessary when extraoral appliances such as headgear are prescribed and may limit their use.

Unilateral Class II elastics are often used on full arches to correct the antero–posterior position of the first molars, premolars and canines. This mechanism of Class II correction has limitations because it relies on patient co-operation. Significant side-effects are associated with the wear of unilateral Class II elastics which depend on the amount and point of application of the force as well as the length of treatment. Among these side-effects are a skewing of the arches with possible development of a maxillary–mandibular midline discrepancy and asymmetric overjet (Fig. 3). Canting of the maxillary anterior occlusal plane can also be observed due to the vertical component of the Class II elastic unilaterally, and significant lower incisor flaring can be observed if this is not

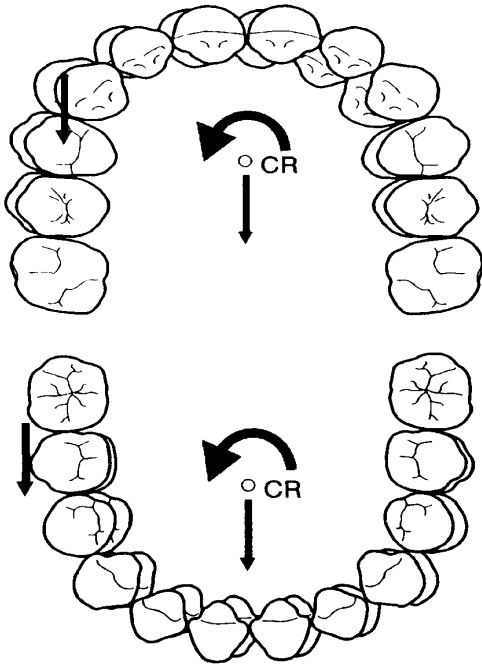


Figure 3 Occlusal aspect of the maxillary and mandibular arches. Unilateral Class II elastic wear results in a skewing of both arches in opposite directions with respect to their centre of resistance (CR).

controlled properly. Posterior teeth may not be free to slide distally so that the entire arch rotates instead of the molars tipping distally. Steepening of the posterior occlusal plane is also observed unilaterally resulting from the vertical component of the Class II elastic.

Sliding jigs associated with unilateral Class II elastic use have also been suggested to correct dental asymmetries (Thurow, 1966; Tweed, 1966). These jigs slide on a continuous archwire and transmit a distal force to the molar from the unilateral Class II elastic. Although the elastic is not directly attached to the main archwire, side-effects from unilateral Class II mechanics can still be observed (Fig. 4a,b).

Unilateral Class II elastic wear has also been used with a coil spring to tip a maxillary first molar distally in an attempt to correct the molar mesio-distal axial inclination. The coil spring delivers a distal force to the molar and an equal and opposite mesial force to the premolars and

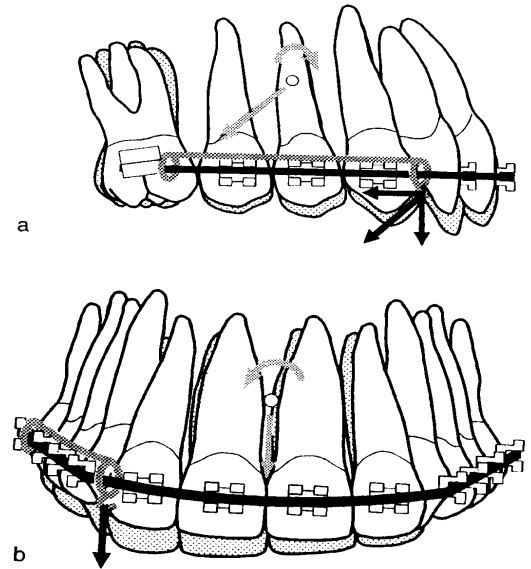


Figure 4 (a) Horizontal and vertical forces resulting from a unilateral Class II elastic used with a sliding jig are shown. (b) In the frontal plane, the unilateral vertical force results in canting of the anterior occlusal plane.

canines. The unilateral Class II elastic delivers a distal force to counteract the mesial force applied by the coil spring, and a vertical force which is responsible for side-effects including canting of the anterior occlusal plane and steepening of the posterior occlusal plane (Fig. 5a,b). The distal force applied by the unilateral Class II elastic may also cause skewing of the arches. The long-term stability of correction involving the use of such Class II mechanics is questionable because it is based on the movement of the entire arch when only molar tip-back is indicated to correct an abnormal mesio-distal axial inclination of this tooth. Flaring of the lower incisors and changes in the cant of the anterior and posterior occlusal planes may also be undesirable.

Unilateral tip-back mechanics using straight continuous archwires or unilateral tip-back bends can also be incorporated in the treatment of dental asymmetries resulting from altered

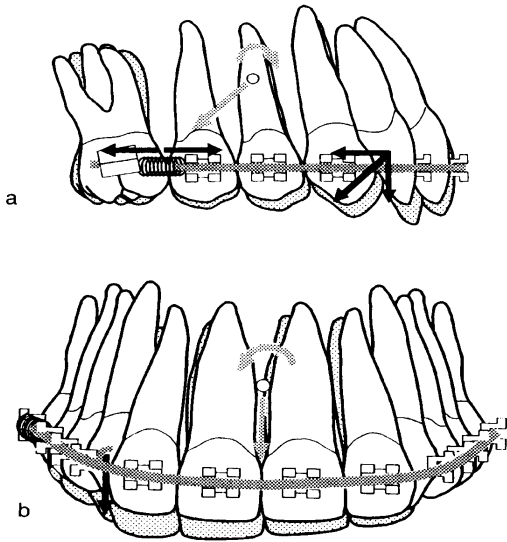


Figure 5 (a) Force system generated by a coil spring associated with unilateral Class II elastic wear. (b) Frontal view showing a canting of the anterior occlusal plane and steepening of the posterior occlusal plane due to unilateral Class II elastic wear.

molar axial inclinations. When unilateral tip-back mechanics are attempted with straight archwires, considerable friction is developed at the bracket and the molar may experience a forward movement of its root without distal movement of its crown (Fig. 6).

Other significant side-effects including canting of the anterior occlusal plane occur as the molar achieves a better axial inclination. The application of a unilateral tip-back moment produces vertical forces, which are intrusive anteriorly and extrusive posteriorly (Fig. 7a). The intrusive force generated on one side of the anterior part of the arch creates a moment around the centre of resistance of the anterior unit (four maxillary incisors). This results in a cant of the anterior occlusal plane which tends to intrude the anterior teeth on the side where the molar uprighting is recommended (Fig. 7b,c).

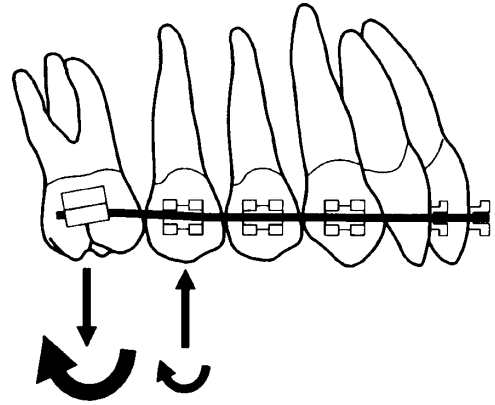


Figure 6 Sagittal view of the force system produced with a straight wire extended through the bracket of a mesially tipped maxillary first molar.

Unless the anterior intrusive force is of very small magnitude and distributed to the rest of the arch through the use of a heavy sectional archwire, this side-effect is difficult to control.

Desired force system to achieve unilateral tip-back

The force system necessary to correct an asymmetric buccal occlusion resulting from the forward tipping of a maxillary permanent first molar will be analysed. In this example, the opposite side of the arch exhibits an ideal Class I occlusion with a normal axial inclination of the maxillary permanent first molar. To correct the axial inclination of the mesially tipped first permanent molar, a tip-back moment is used on this side only (Fig. 8). A single distal force applied at the molar bracket can also be used to produce tip-back but the use of a couple involves less undesirable side-effects. The goal is to maintain a good occlusion on the Class I side and not to produce incisor side-effects.

It is possible by connecting the right and left first molars with a transpalatal archwire or horseshoe arch to apply a tip-back moment on the side presenting the tipped molar (Burstone and Manhartsberger, 1988; Burstone, 1989, 1994). The molar on the opposite side experiences a tip-forward moment (Fig. 9). This undesirable side-effect can be controlled by

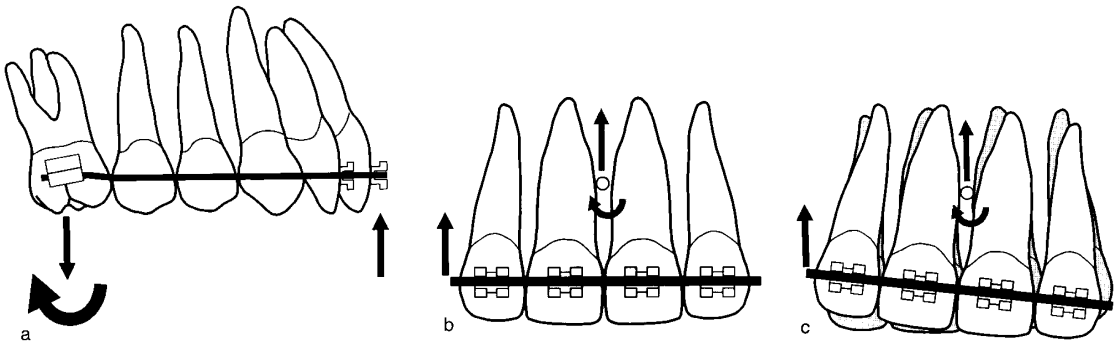


Figure 7 (a) Sagittal view of the force system produced with a 2 × 4 appliance with tip-back bends mesial to the first molar. (b) Frontal view of the unilateral intrusive force resulting from a unilateral tip-back. (c) Cant of the occlusal plane due to a unilateral intrusive force applied at some distance from the centre of resistance of the anterior teeth.

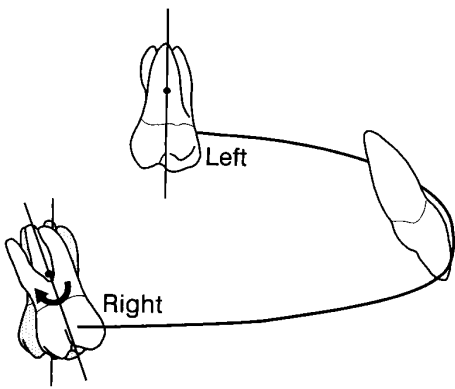


Figure 8 Desired force system to tip-back a molar unilaterally.

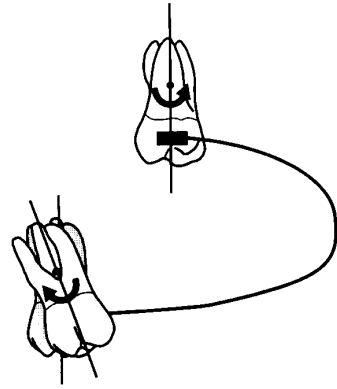


Figure 9 Force system generated when a tip-back moment is applied unilaterally with a transpalatal arch.

consolidating the rest of the dental arch using a heavy archwire. This approach can only be used in the permanent dentition and is not suitable in the mixed dentition because of the limited number of permanent teeth present in the arch. Another approach is described below.

Bilateral tip-back moments to correct the molar axial inclination may be produced by using a three-piece base arch (Fig. 10) (Shroff *et al.*, 1995). Bilateral tip-back springs are hooked to the distal extensions of an anterior segment of wire which includes the four maxillary incisors. Anterior intrusive forces and posterior extrusive forces are produced with the molar tip-back moments. The intrusive force is placed through

the centre of resistance of the upper incisors to prevent flaring. Intrusion of the four maxillary incisors is a desirable side-effect of bilateral tip-back mechanics which can be used in the presence of a deep overbite. As tip-back of the molars occurs, the anterior hooks of the tip-back springs slide distally along the distal extension of the anterior segment of wire. The position of these hooks needs to be modified during treatment to maintain the point of application of the intrusive force through the centre of resistance of the upper incisors. In cases where no intrusion of the maxillary anterior teeth is indicated, the anterior segment of wire is

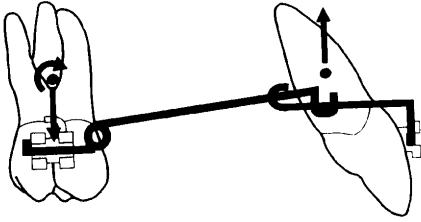


Figure 10 Lateral view of a three-piece base arch.

extended to the right and left canines to minimize the amount of intrusion.

It is possible to combine an asymmetric lingual arch activation with bilateral tip-back springs to correct an asymmetric buccal occlusion associated with a deep overbite. In these cases, a bilateral tip-back moment is applied to the right and left molars and intrusion of the four incisors is obtained using a three-piece base arch (Shroff *et al.*, 1995). Simultaneously, a palatal arch is used to deliver a unilateral tip-back moment to the side requiring the molar axial inclination correction. The molar on the opposite side is maintained in its original position because of opposing moments from the intrusion spring and the lingual arch.

The three-piece base arch is composed of an anterior segment of wire placed passively into the brackets of the four incisors. This anterior segment of wire is fabricated from $0.021 \times 0.025''$ stainless steel wire to obtain high rigidity. Tip-back moments are applied to the molars bilaterally by using tip-back springs extending from the auxiliary tube of the molar to the distal extension of the anterior segment of wire. The anterior portion of this spring has a hook that is free to slide along the distal extension of the anterior segment of wire. It is important that the crown of the molar is free to move distally as its axial inclination improves. These tip-back springs are fabricated from $0.017 \times 0.025''$ TMA wire and 70 g of intrusive force can be applied on the right and left sides of the anterior segment of wire. This mechanism delivers a moment of approximately 2100 g/mm if the distance between the anterior and posterior teeth is 30 mm. Simultaneously, a transpalatal or horseshoe arch made of $0.032 \times$

$0.032''$ TMA or $0.030''$ stainless steel is used to deliver equal and opposite moments to each side of the arch.

The resulting force system includes an increased tip-back moment on the side which needs the molar axial inclination correction (Fig. 11a). The molar on the other side of the arch experiences a tip-forward moment delivered by the palatal arch and is counteracted by the tip-back moment delivered by the tip-back springs. These two moments should cancel each other, resulting in maintenance of an ideal occlusion on this side of the arch. Equal intrusive forces are applied on each side of the anterior segment of teeth and intrusion of the anterior teeth is obtained, thus helping the overbite correction (Fig. 11b). Tip-back of the molar is obtained rapidly. The amount of extrusive force experienced by the molars may be counteracted by the forces of occlusion. Further control of the vertical dimension during this phase of treatment can be achieved using a chin cap with a straight vertical pull. The chin cap is worn at night and will help control the molar extrusion resulting from tip-back mechanics. Once the axial inclination of the right and left molars are symmetric, control of further tip-back of these teeth and of the vertical dimension during intrusion may be achieved by using a high-pull headgear with a pull directed above the centre of resistance of the molars.

Clinical applications

The first major step of the treatment corrects the axial inclination of the tipped molar to achieve better symmetry of the buccal occlusion and to create space posteriorly. Before this is attempted, good alignment of the four maxillary incisors is achieved and a rigid anterior segment of wire is placed into the brackets of the four maxillary incisors with a bilateral distal extension. Tip-back springs are activated equally on both sides and bilateral tip-back mechanics are initiated. Careful identification of the position of the centre of resistance of the four maxillary incisors is undertaken on a lateral cephalometric head film. The intrusive force is applied through the centre of resistance of the four maxillary

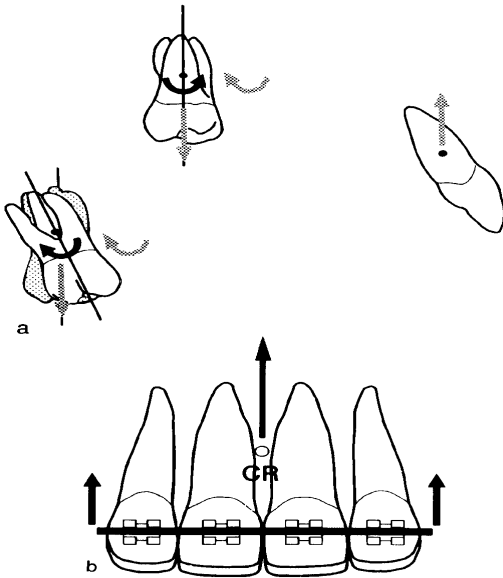


Figure 11 (a) Force system resulting from the simultaneous application of bilateral tip-backs (grey arrows) using a three-piece base arch and the application of a unilateral tip-back (black arrows) using a transpalatal arch. (b) The anterior segment of teeth is intruded.

incisors thus intruding them. Simultaneously, a palatal arch is placed with a tip-back/tip-forward activation to correct the asymmetric side and hold the opposite molar in its correct position. A tip-back bend is placed at the juncture between the vertical and the horizontal parts of the palatal arch, and the entire palatal arch is twisted by incorporating a bend at its apex. This prevents an undesirable mesial force on the tipped molar. For a horseshoe arch, the tip-back activation is placed by introducing a smooth curvature in the arch (Burstone, 1989). No buccal segments of wire are placed to allow the premolars and canine to drift back as the molar axial inclination is correcting (Figs 12a,b and 13a,b). Transseptal fibres are partly responsible for the distal migration of the premolars and canine. A figure-of-eight ligature wire may also

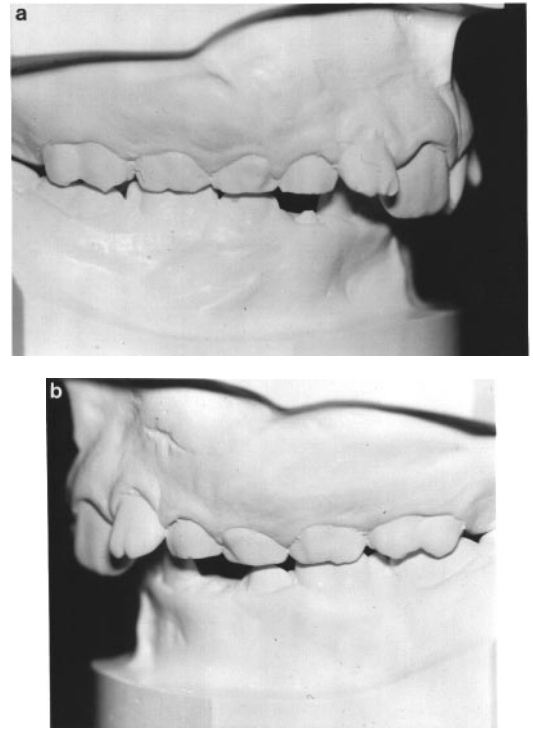


Figure 12 Pretreatment views of the occlusion on models. (a and b) Right and left buccal occlusions. The right and left buccal occlusions are asymmetric because of a difference in the mesio-distal axial inclination of the maxillary permanent first molars. The left permanent first molar is tipped forward.

be extended from the molar to the premolars and canine to encourage their distal drift. Disto-palatal rotation of the premolars and canine may be prevented by simultaneously using a figure-of-eight ligature on the palatal aspect of these teeth. Intrusion of the maxillary incisors is a side-effect of tip-back mechanics used advantageously to correct the deep overbite.

Monitoring of progress is carried out at regular intervals (every 4 weeks) and once the desired correction is achieved the palatal arch is made passive to the new molar position.

Unilateral tip-back mechanics are primarily used to correct molar mesio-distal axial inclination in cases of dental asymmetries as described in this paper. However, in some cases of skeletal asymmetries involving small skeletal discrepancies, unilateral tip-back mechanics may be successfully used to produce dental compensations.

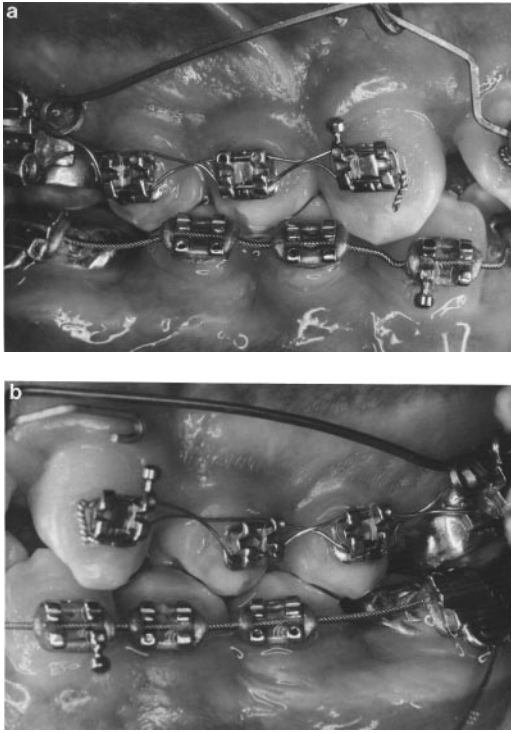


Figure 13 Intraoral views after correction of the molar axial inclination on the left side. (a and b) Right and left buccal occlusions.

Conclusion

The correction of dental asymmetry is a fundamental component of achieving an optimum treatment result. Dental asymmetries resulting from an altered mesio-distal molar axial inclination can be successfully corrected orthodontically without side-effects. Undesirable side-effects resulting from commonly used mechanics include canting of the occlusal plane and incisor flaring. The principles of the segmented arch technique are helpful for designing an appliance that will deliver a controlled and statically determinate force system.

A method has been presented for unilaterally tipping a molar distally that relies on tip-back moments and not a distal force. By combining a lingual arch and tip-back springs, the molar tips back on the desired side, the occlusion on the opposite side is maintained and reciprocally the incisors are intruded.

Address for correspondence

Dr Bhavna Shroff
Department of Orthodontics
University of Maryland Dental School
666 W. Baltimore Street
Baltimore, MD 21201
USA

Acknowledgements

Thanks are extended to Ms Jo-Ann Walker and Ms Barbara Vallonga for preparing the manuscript and to Ms Carol Wilkins for the computer-generated graphics.

References

- Burstone C J 1962 The rationale of the segmented arch. *American Journal of Orthodontics* 48: 805–821
- Burstone C J 1966 Mechanics of the segmented arch technique. *Angle Orthodontist* 36: 99–120
- Burstone C J 1981 Variable modulus orthodontics. *American Journal of Orthodontics* 80: 1–16
- Burstone C J 1985 Applications of bioengineering to clinical orthodontics. In: Graber T M (ed.) *Current orthodontic concepts and techniques*, 2nd edn. W B Saunders, Philadelphia
- Burstone C J 1989 Precision lingual arches: active applications. *Journal of Clinical Orthodontics* XXIII: 101–109
- Burstone C J 1994 The precision lingual arch. Lingual cap attachment. *Journal of Clinical Orthodontics* XXVIII: 151
- Burstone C J, Manhartberger C 1988 Precision lingual arches: passive applications. *Journal of Clinical Orthodontics* XXII: 444–451
- Burstone C J, Baldwin J J, Lawless D T 1961 The application of continuous force to orthodontics. *Angle Orthodontist* 31: 1–14
- Garland Hershey H, Houghton C W, Burstone C J 1981 Unilateral face bows: a theoretical and laboratory analysis. *American Journal of Orthodontics* 79: 229–249
- Haack D C, Weinstein S 1958 The mechanics of centric and eccentric cervical traction. *American Journal of Orthodontics* 44: 346–357
- Romeo D A, Burstone C J 1977 Tip-back mechanics. *American Journal of Orthodontics* 72: 414–421
- Shroff B, Lindauer S J, Burstone C J, Leiss J B 1995 Segmented approach to simultaneous intrusion and space closure: biomechanics of the three piece base arch appliance. *American Journal of Orthodontics and Dentofacial Orthopedics* 107:136–143
- Smith R J, Burstone C J 1984 Mechanics of tooth movement. *American Journal of Orthodontics* 85: 294–307
- Thurow R 1966 *Edgewise orthodontics*. C V Mosby Co., St Louis
- Tweed C 1966 *Clinical orthodontics*. C V Mosby Co., St Louis